

Clinical image

A Case of a Carcinoid Tumour With Diffuse Tracheal Invasion



Caso de tumor carcinoide con invasión difusa de la tráquea

Cengiz Özdemir, Sinem Nedime Sökücü*

Yedikule Chest Disease and Thoracic Surgery Training and Research Hospital, Istanbul, Turkey

A 45-year-old man diagnosed with an atypical carcinoid tumour had undergone a left upper lobectomy completed with mediastinal lymphadenectomy. The patient was out of follow-up. He presented with dyspnoea and multiple metastases in his liver 5 years after the original diagnosis. A liver biopsy verified neuroendocrine tumour metastases, and the patient was started on everolimus. A thoracic computed tomography scan was taken (Fig. 1a). Rigid

bronchoscopy revealed 3-cm long grape like nodules, starting 5 cm distal to the vocal cords and obstructing the tracheal lumen 80% (Fig. 1b). The entrance to the right main bronchus and segment openings of distal bronchi were obstructed by nodular infiltrations. Nodular lesions in the trachea were coagulated with a diode laser (980 nm wavelength, 4–25 W, pulsed mode), and the airway was cleared. Argon plasma coagulation was used at the base of the lesions, and at the entrance of both main bronchi, to control haemorrhaging (Fig. 1c). The patient died 1 year after treatment. Survival with atypical carcinoid tumours is poor compared to typical carcinoids, but still better than for other lung cancers. Endobronchial treatment is an effective method for symptom palliation in patients with atypical carcinoid tumours and a malignant airway obstruction.

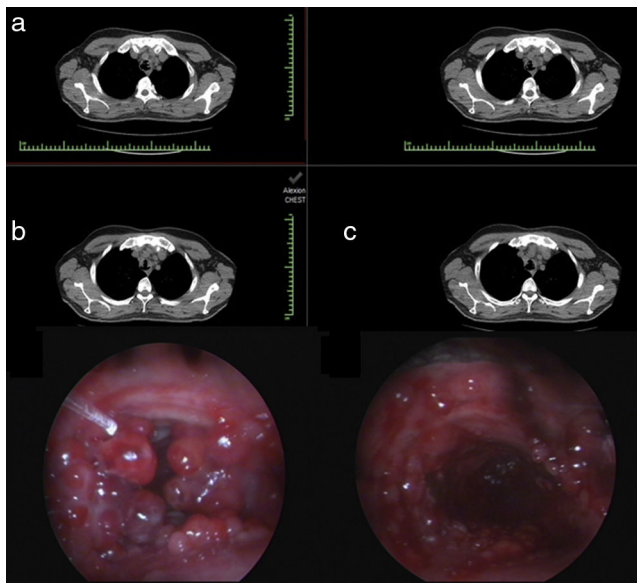


Fig. 1. Tracheal lesions on the thorax computed tomography of the patient (a) Endobronchial view before (b) and after treatment (c).

* Corresponding author.
E-mail address: sinemtimur@yahoo.com (S.N. Sökücü).