

account blood cell metabolism: these authors studied changes in the concentration of pO<sub>2</sub> of oxygenated water, avoiding the use of blood per se, and obtained similar results.

It is important to note that in studies with a higher initial pO<sub>2</sub> than ambient pO<sub>2</sub>, the diffusion gradient of the gases is reversed and pO<sub>2</sub> diminishes with time,<sup>12,14</sup> a finding that only goes to reinforce the hypothesis of simple gas diffusion.

Our results also clearly support this physical diffusion theory, since pO<sub>2</sub> variability increases depending on atmospheric pressure in a statistically significant manner, a factor that had never been previously analyzed.

In summary, it seems clear that over time, pO<sub>2</sub> in ABG tends to increase, and that this variation could be directly associated with plastic syringes and the diffusion of gases through this porous material. Our study supports this theory and reveals a direct relationship of these variations with atmospheric pressure.

Despite the fact that ABG determinations vary significantly with time, they do so to an extent that is insignificant in clinical practice. It may be of interest, in the future, to expand the study to different time points.

## References

1. Barerá JA, Giner J. Evaluación de la función pulmonar Gasometría arterial. Manual separ de procedimientos. SEPAR; 2002.
2. Rodríguez Rosin R, Agustí García Navarro A, Burgos Rincón F. Normativa sobre la gasometría arterial. Arch Bronconeumol. 1998;34:142–53.
3. Giner J, Macian V, Burgos F, Berrojalbiz A, Martín E. La punción arterial en nuestro ámbito. Seguimiento de la normativa SEPAR 1987. Arch Bronconeumol. 1994;30:394–8.
4. Normativa SEPAR sobre la gasometría arterial. Recomendaciones SEPAR; 1987.
5. Alquezar Fernandez M, Burgos Rincon F, Peinador Aguilar R, Perpina Tordera M. Gasometría arterial Manual separ de procedimientos. SEPAR; 2017. ISBN 978-84-947771-4-1.
6. Brusasco V, Crapo R, Viegi G. ATS/ERS task force: standardisation of lung function testing. Eur Respir J. 2005;26:153–61.

7. Sahni AS, González H, Tulaimat A. Effect of arterial puncture on ventilation. Heart Lung. 2017;46:149–52.
8. Liss HP, Payne CP Jr. Stability of blood gases in ice and at room temperature. Chest. 1993;103:1120–2.
9. Mahoney JJ, Harvey JA, Wong RJ, van Kessel AL. Changes in oxygen measurements when whole blood is stored in iced plastic or glass syringes. Clin Chem. 1991;37:1244–8.
10. Knowles TP, Mullin RA, Hunter JA, Douce FH. Effects of syringe material, sample storage time, and temperature on blood gases and oxygen saturation in arterialized human blood samples. Respir Care. 2006;51:732–6.
11. Schmidt C, Muller-Plathe O. Stability of pO<sub>2</sub>, pCO<sub>2</sub> and pH in heparinized whole blood samples: influence of storage temperature with regard to leukocyte count and syringe material. Eur J Clin Chem Clin Biochem. 1992;30:767–73.
12. Pretto JJ, Rochford PD. Effects of sample storage time, temperature and syringe type on blood gas tensions in samples with high oxygen partial pressures. Thorax. 1994;49:610–2.
13. Fletcher G, Barber JL. Effect of sampling technique on the determination of PaO<sub>2</sub> during oxygen breathing. J Appl Physiol. 1966;21:462–8.
14. Beaulieu M, Lapointe Y, Vinet B. Stability of PO<sub>2</sub>, PCO<sub>2</sub>, and pH in fresh blood samples stored in a plastic syringe with low heparin in relation to various blood-gas and hematological parameters. Clin Biochem. 1999;32:101–7.

Ana Gómez-García,<sup>a</sup> Tomás Ruiz Albi,<sup>b</sup> José Ignacio Santos Plaza,<sup>a</sup> Andrea Crespo Sedano,<sup>a</sup> Ana Sánchez Fernández,<sup>c</sup> Graciela López Muñiz,<sup>a</sup> Tania Álvaro de Castro,<sup>a,b,c</sup> Pilar Revilla Gutiérrez,<sup>a</sup> Josefa Villar Muñoz,<sup>a</sup> Gloria Martínez González,<sup>a</sup> Félix del Campo Matías<sup>b,\*</sup>

<sup>a</sup> Hospital Universitario Río Hortega, Valladolid, Spain

<sup>b</sup> Universidad de Valladolid, Spain

<sup>c</sup> Hospital Universitario de Salamanca, Spain

\* Corresponding author.

E-mail address: fsas@telefonica.net (F. del Campo Matías).

1579-2129/

© 2019 SEPAR. Published by Elsevier España, S.L.U. All rights reserved.

## Pulmonary Emphysema in a Child With Alpha-1 Antitrypsin Deficiency: Evaluation of 2 Years of Intravenous Augmentation Therapy



### Enfisema pulmonar en un niño con deficiencia de alfa 1 antitripsina: evaluación tras dos años con terapia de aumento

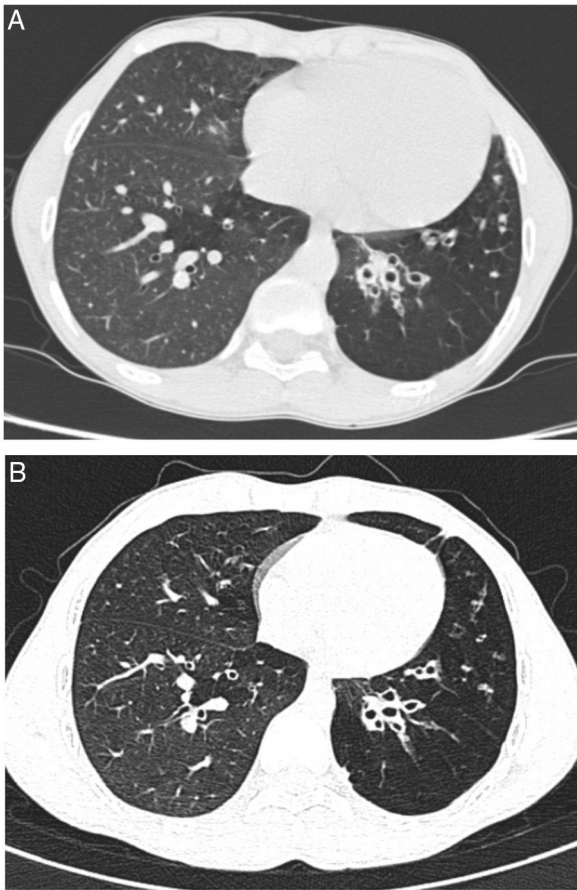
Dear Editor:

Alpha-1 antitrypsin deficiency (AATD) is an autosomal codominant condition, known to predispose to early onset pulmonary emphysema and chronic obstructive pulmonary disease. Generally, lung manifestations of the disease affect smokers at the third or fourth decade of life and so far, intravenous injections of purified alpha-1 antitrypsin are the single target therapy for AATD. Given that lung function in children is typically normal, augmentation therapy has never been systematically studied in pediatric population.

We report a case of a male neonate born at 40 weeks of gestation, weighing 2750 g, with an uneventful postnatal period. His first year of life was marked by downward crossing of weight percentile, recurrent suppurative otitis media and two hospitalizations due to respiratory infections. At 9 months of age, routine laboratory investigation revealed anemia (11.8 g/dL) and elevated liver enzymes (aspartate transaminase 596 U/L, alanine transaminase 722 U/L,

alkaline phosphatase 239 U/L and gamma-glutamyl transpeptidase 75 U/L). Due to decreased alpha-1 antitrypsin (AAT) serum concentration (50 mg/dL) gene sequencing (*SERPINA1*) was performed and revealed a ZPlowell genotype. There was no ultrasound evidence of liver impairment. The child's follow-up was interrupted due to a problematic social situation. His family medical history was unremarkable. However, a significant passive smoke exposure due to paternal smoking was reported. He returned to our observation at age 10 years, complaining of recurrent productive coughing, wheezing as well as dyspnea on exertion. On physical examination the patient presented with pale skin, weak appearance and low weight for his age (10th percentile). The chest auscultation revealed diffuse expiratory wheezing and bilateral basal crackles. Pulmonary function tests indicated a non-reversible mild airflow obstruction (FEV1 71.3% pred, FEV1/FVC 74% pred). Laboratory studies showed aggravated anemia, peripheral eosinophilia, elevated total IgE and sensitization to common inhalant allergens (RAST positive). At this time serum level of AAT was 36.7 mg/dL. Chest computed tomography (CT) imaging showed lower lobe predominant panlobular emphysema and cystic bronchiectasis (Fig. 1).

He started inhaled therapy with medium-dose corticosteroid (budesonide 160 mcg) plus long-acting  $\beta$ -agonist (formoterol 4.5 mcg) and leukotriene receptor antagonist (montelukast 10 mg). Despite optimized anti-inflammatory and bronchodilator therapy



**Fig. 1.** Computed tomography of the chest, before (A) and after 19 months of treatment (B), showing no progression of the emphysema or bronchiectasis.

associated with lifestyle preventive measures, the child remained symptomatic with recurrent use of antibiotic therapy owing to respiratory infections. Spirometric monitoring over 1 year demonstrated persistent mild airflow obstruction (FEV1 77.8% pred) and air trapping (RV 181.8% pred). At age 14 years, given the severity of emphysema and the risk of disease progression, and in the absence of therapeutic alternatives, it was decided to start AAT augmentation therapy. Up till now, he has been receiving weekly intravenous injections with 60 mg/kg of AAT (Prolastin, Bayer Corporation). So far, 132 infusions have been administered without complications. Regular treatment with inhaled corticosteroids and bronchodilators was left unchanged. Clinically, in the first two years of treatment, the patient has experienced a significant improvement in his overall condition (weight gain up to the 25th percentile) and respiratory symptoms. He had no emergency department admissions nor hospitalizations in the last two years. Functional reassessment at 18 months of treatment showed stable FEV1 and improvement of air trapping (FEV1 77.8% pred; RV 168.9% pred). Stability of pulmonary emphysema and bronchiectasis was observed on high resolution chest CT (Fig. 1).

Studies on the natural history of AATD indicated that emphysema usually begins in the third or fourth decade of life in those exposed to cigarette smoking.<sup>1</sup> Although there is paucity

of data in the pediatric age group, children and adolescents with AATD have not been shown to have significant lung function abnormalities.<sup>2</sup> However, Hird et al. have suggested a tendency to hyperinflation in affected children with liver disease.<sup>3</sup> Our patient suffers from severe deficiency due to ZPlowell genotype. Plowell (rs121912714; p.Asp256Val) is a rare *SERPINA1* variant that has been associated with exaggerated intracellular degradation of newly synthesized protein and to 24% of normal serum levels. Compound heterozygotes with severe deficient Z allele were reported to have an increased risk of emphysema in adulthood.<sup>4</sup> In this case, it is possible that tobacco smoke exposure, coexisting inflammatory disease (atopic asthma), frequent low respiratory tract infections and poor nutritional status have contributed to pulmonary function deterioration and emphysema development at such early age. This case highlights the importance of family-based smoking intervention to attain a nonsmoking lifestyle in children with AATD. It is worth noting that determination of AAT serum concentration should be considered in the panel of tests for investigation of adolescents with respiratory symptoms unresponsive to usual asthma treatment interventions.<sup>5,6</sup> In case of AATD, the evaluation must be completed with genotyping and, eventually *SERPINA1* sequencing to exclude rare deficiency alleles.

Intravenous administration of AAT is currently the only specific treatment for AATD. Evidence from randomized placebo-controlled clinical trials showing that augmentation therapy in adult patients with severe AATD is safe and effective at reducing the progression of emphysema as assessed by CT densitometry,<sup>7,8</sup> have supported its recommendation in international guidelines.<sup>9</sup> In addition, a large observational study reported decreased mortality and slower FEV1 decline in subjects receiving augmentation therapy as compared with those not receiving therapy.<sup>10</sup>

We report the second case described in the literature on augmentation therapy for AATD at pediatric age.<sup>11</sup> On both cases, a good safety profile and significant clinical benefit were observed. Based on these favorable outcomes, we believe that in selected children with AATD related-lung disease, augmentation therapy may provide the same benefits demonstrated in adults. Therefore, we encourage research groups to include children and adolescents in large AATD clinical trials.

## References

1. Brantly ML, Paul LD, Miller BH, Falk RT, Wu M, Crystal RG. Clinical features and history of the destructive lung disease associated with alpha-1-antitrypsin deficiency of adults with pulmonary symptoms. *Am Rev Respir Dis.* 1988;138:327–36.
2. Sveger T, Piitulainen E, Arborelius MJ. Lung function in adolescents with alpha 1-antitrypsin deficiency. *Acta Paediatr.* 1994;83:1170–3.
3. Hird MF, Greenough A, Mieli-Vergani G, Mowat AP. Hyperinflation in children with liver disease due to alpha-1-antitrypsin deficiency. *Pediatr Pulmonol.* 1991;11:212–6.
4. Holmes MD, Brantly ML, Crystal RG. Molecular analysis of the heterogeneity among the P-family of alpha-1-antitrypsin alleles. *Am Rev Respir Dis.* 1990;142:1185–92.
5. Alpha1-antitrypsin deficiency: memorandum from a WHO meeting. *Bull WHO.* 1997;75:397–415.
6. Tubío-Pérez RA, Blanco-Pérez M, Ramos-Hernández C, Torres-Durán M. Alpha-1 antitrypsin deficiency associated with the P1\*Q0ourém allele in a 2-year-old girl and family study. An unusual case. *Arch Bronconeumol.* 2018;54:228–30.
7. Dirksen A, Piitulainen E, Parr DG, Deng C, Wencker M, Shaker SB, et al. Exploring the role of CT densitometry: a randomised study of augmentation therapy in alpha1-antitrypsin deficiency. *Eur Respir J.* 2009;33:1345–53.
8. Chapman KR, Burdon JG, Piitulainen E, Sandhaus RA, Seersholm N, Stocks JM, et al. Intravenous augmentation treatment and lung density in severe  $\alpha$ 1 antit-

- rypsin deficiency (RAPID): a randomised, double-blind, placebo-controlled trial. *Lancet*. 2015;386:360–8.
9. Miravittles M, Dirksen A, Ferrarotti I, Koblizek V, Lange P, Mahadeva R, et al. European respiratory society statement: diagnosis and treatment of pulmonary disease in  $\alpha_1$ -antitrypsin deficiency. *Eur Respir J*. 2017;50:1700610.
  10. Survival and FEV<sub>1</sub> decline in individuals with severe deficiency of alpha-1 antitrypsin. The Alpha-1 Antitrypsin Deficiency Registry Study Group. *Am J Respir Crit Care Med*. 1998;158:49–59.
  11. Griese M, Brügggen H. Intravenous alpha1-antitrypsin in a child with deficiency and severe lung disease. *Eur Respir J*. 2009;34:278–9.

Maria Esteves Brandão,<sup>a,\*</sup> Bebiana Conde,<sup>a</sup> Susana Seixas,<sup>b,c</sup>  
Joelma Clotilde Silva,<sup>a</sup> Ana Fernandes<sup>a</sup>

<sup>a</sup> Respiratory Department, Centro Hospitalar de Trás-os-Montes e Alto Douro, Vila Real, Portugal

<sup>b</sup> Institute of Molecular Pathology and Immunology of the University of Porto, Porto, Portugal

<sup>c</sup> Instituto de Investigação e Inovação em Saúde (I3S), Porto, Portugal

\* Corresponding author.

E-mail address: [mariaestevesbrandao@gmail.com](mailto:mariaestevesbrandao@gmail.com)

(M. Esteves Brandão).

1579-2129/

© 2019 SEPAR. Published by Elsevier España, S.L.U. All rights reserved.