

Clinical Image

Pebble-like Lesions: A Rare Sight in The Bronchial Tree[☆]



Imagen poco habitual en el árbol bronquial: como «piedras de río»

Anna Sala Marín,* Ruben Lera Alvarez, Alejandro Betancurt Diaz

Servicio de Neumología, Hospital Universitario Dr. Peset, Valencia, Spain

Aspergilloma is the most common and best recognized form of pulmonary aspergillosis.¹ All species of *Aspergillus* can cause aspergilloma, which develops by colonizing a pre-existing space, cyst or bulla.² We report the case of an aspergilloma forming in a tuberculous cavity, with the unusual bronchoscopy finding resembling pebbles.

A 55-year-old woman, smoker, 10 pack-years, consulting due to chronic cough. Clinical history included pulmonary tuberculosis 25 years previously, for which she received complete treatment. Chest computed tomography revealed fibrotic atelectasis in the left upper lobe with pleural thickening, fibrous tracts, nodules, bronchiectasis, and cavities occupied by mycetomas. Marked hypertrophy was observed in the left bronchial artery trunk and the systemic vessels leading to the tuberculous fibrotic lesion. Skin prick test was positive for *Aspergillus*+++ , total IgE was 899 kU/l, with specific IgE response to *Aspergillus fumigatus* of 11.6 kUA/l. Repeated sputum cultures were negative. Bronchoscopy was performed, revealing multiple brownish, nodular lesions, resembling pebbles in the entrance to the subsegmentary bronchus of the left upper lobe (Fig. 1). *Aspergillus* spp. hifae with no invasion of the vessels or the lung parenchyma were found in the lesion biopsy. The patient was treated surgically, due to the high risk of hemoptysis and abundant vascularization of the lesion, which was exposed to the main bronchi.

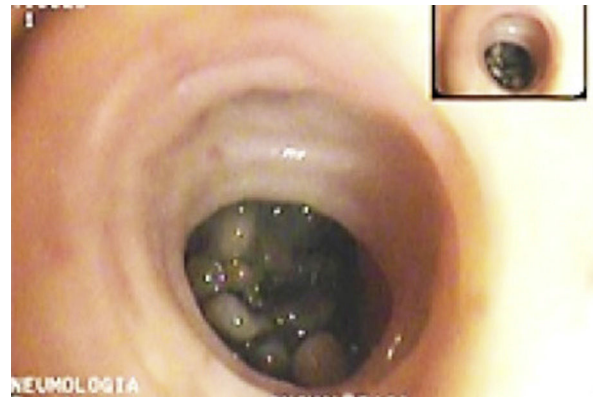


Fig. 1. Bronchoscopic image of the left upper lobe segmentary bronchus resembling pebbles.

References

1. Díaz Sánchez C, López Viña A. *Aspergillus* y pulmón. Arch Bronconeumol. 2004;40:114–22.
2. Fortún J, Meije Y, Fresco G, Moreno S. Aspergilosis: formas clínicas y tratamiento. Enferm Infecc Microbiol Clin. 2012;30:201–8.

[☆] Please cite this article as: Sala Marín A, Lera Alvarez R, Betancurt Diaz A. Imagen poco habitual en el árbol bronquial: como «piedras de río». Arch Bronconeumol. 2016;52:611.

* Corresponding author.

E-mail address: anniuscka@hotmail.com (A. Sala Marín).