

Clinical Image

Multiple Cervicomedial Hamartomas Associated with Lymphangiomyomatosis

Veysel Ayyildiz^a, Yener Aydin^{b,c,*}, Hayri Ogul^{c,d}

^a Department of Radiology, Suleyman Demirel University, Medical Faculty, Isparta, Turkey

^b Department of Thoracic Surgery, Ataturk University, Medical Faculty, Erzurum, Turkey

^c Anesthesiology, Clinical Research Office, Ataturk University, Medical Faculty, Erzurum, Turkey

^d Department of Radiology, Duzce University, Medical Faculty, Duzce, Turkey

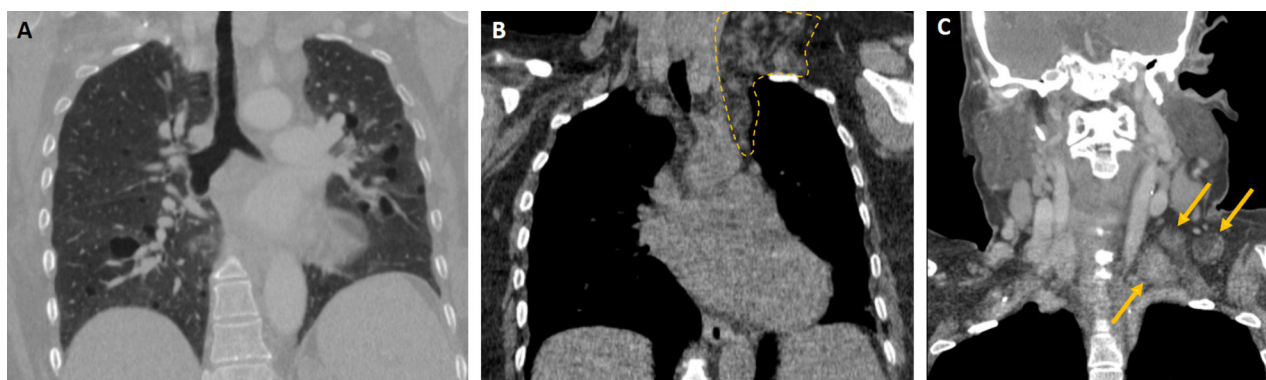


Fig. 1. Coronal chest CT scan (A) in mediastinal window demonstrates multiple parenchymal cystic lesions. Coronal chest (B) and neck (C) CT scans show multiple hamartomatous lesions (circle and arrows) with complex lipid density.

A 61-year-old female patient presented with a dyspnea for several years. She had a history of lymphangiomyomatosis and had undergone a right nephrectomy for angiomyolipoma. Multiple hamartomatous lesions were detected in the mediastinal and cervical regions on control thoracic computed tomography (Fig. 1).

Angiomyolipoma is a tumoral lesion involving various combinations of smooth muscle, adipose tissue and vascular structures that most commonly affects the kidneys, but can also be observed in the liver, lung, lymph nodes, mediastinum, and retroperitoneal soft tissues. They are almost always benign neoplasms. However, they can cause massive or even fatal retroperitoneal hemorrhage. Lymphangiomyomatosis is a pathology that can diffusely affect the lungs and cause respiratory failure, spontaneous pneumothorax or chylothorax. There is the theory that lymphangiomyomatosis cells may actually arise from these angiomyolipomas.^{1,2} In these cases, resection for mediastinal and cervical angiomyolipomas can be considered, if possible.

Financial

The authors received no financial support for the research and/or authorship of this article.

Conflict of interest

The authors declare that they have no conflict of interest to the publication of this article.

References

- Cooper A, Baugh L, Kelley S, Huang H, Guileyardo J. Pulmonary lymphangiomyomatosis associated with aggressive renal angiomyolipoma. *Proc (Bayl Univ Med Cent)*. 2018;31:81–3.
- Vaggers S, Rice P, Somani BK, Veeratterapillay R, Rai BP. Evidence-based protocolled management of renal angiomyolipoma: a review of literature. *Turk J Urol*. 2021;47 Suppl. 1:S9–18.

* Corresponding author.
E-mail address: dryeneraydin@hotmail.com (Y. Aydin).