

Clinical Image

Successful Surgical Treatment of a Giant Pulmonary Vein Ewing's Sarcoma Invading Left Atrium

Tratamiento quirúrgico exitoso de un sarcoma de Ewing gigante de la vena pulmonar que invade la aurícula izquierda

F. Javier González-García^{a,*}, José Joaquín Domínguez del Castillo^b, Ángel Salvatierra Velázquez^a

^a Department of Thoracic Surgery and Lung Transplantation, University Hospital Reina Sofía, Córdoba, Spain

^b Department of Cardiovascular Surgery and Heart Transplantation, University Hospital Reina Sofía, Córdoba, Spain

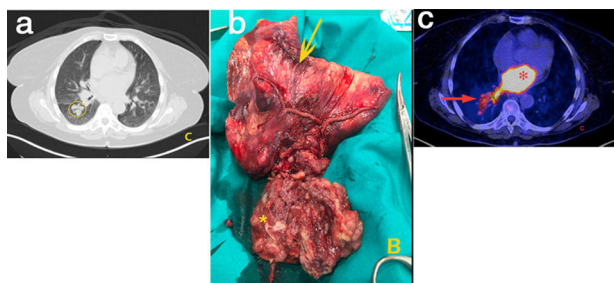


Fig. 1. (A) PET/CT image showing a hypermetabolic mass extending from the pulmonary vein (arrow) to the left atrium (asterisk). (B) Right lower lobectomy (arrow) with intra-atrial mass (arrow). (C) CT scan showing multiple parenchymal metastases.

A 55-year-old woman underwent a routine pelvic magnetic resonance, identifying an inguinal lymph node highly suspicious of malignancy (Fig. 1).

A biopsy of the adenopathy suggested an Ewing sarcoma's metastasis. A body positron emission tomography (PET) only showed a hypermetabolic (Standardized Uptake Value of 13) mass located at the right inferior lobe (*) extending towards the left atrium (arrow) through the inferior pulmonary vein (A).

The patient was submitted for radical surgery. Through an anterolateral thoracotomy and under cardiocirculatory bypass, with cardiac arrest, an en bloc right lower lobectomy with partial atrial resection and mass excision was performed (B). An autologous pericardial patch was used to reconstruct the left atrium.

The postoperative course was uneventful and the patient was discharged on the 6th postoperative day. Definitive histopathology findings were consistent with an Ewing's sarcoma from the inferior pulmonary extending towards the left atrium (arrow). Multiple parenchymal sarcoma foci were founded in the resected right inferior lobe, as expected in the preoperative CT scan. (circle) (C). Adjuvant Adriamycin-based treatment was performed.

Up to 20–30% of Ewing's sarcomas are extraosseal,^{1,2} appearing typically in older ages and females.¹ International guidelines recommend a multidisciplinary treatment including radical surgery, radiation and chemotherapy.^{1,2}

References

1. Lynch AD, Gani F, Meyer CF, Morris CD, Ahuja N. Extraosseal versus Skeletal Ewing Sarcoma in the adult population: controversies in care. *J Surg Oncol.* 2018;27:373–9.
2. Kulkarni SK, Moorthy N, Somanna S, Nanjappa MC. A rare case of Ewing's sarcoma/primitive neuroectodermal tumor metastasizing to left atrium through left inferior pulmonary vein. *Echocardiography.* 2018;35:885–8.

* Corresponding author.

E-mail address: fjaviergonzalez@outlook.com (F.J. González-García).